


FocalPoints

Clinical Modules for Ophthalmologists

VOLUME XXXIII NUMBER 8
AUGUST 2015

Understanding Intraocular Lenses: The Basics of Design and Material

Steven Dewey, MD



REVIEWERS AND CONTRIBUTING EDITORS

D. Michael Colvard, MD, Lisa B. Arbisser, MD, Editors for Cataract Surgery
Sharon L. Jick, MD, Basic and Clinical Science Course Faculty, Section 11
Dasa V. Gangadhar, MD, Practicing Ophthalmologists Advisory Committee for Education

CONSULTANTS

Ricardo G. Glikin, MD
Richard S. Hoffman, MD

Focal Points Editorial Review Board

Eric Paul Purdy, MD, Bluffton, IN
Editor in Chief; Oculoplastic, Lacrimal, and Orbital Surgery

Lisa B. Arbisser, MD, Bettendorf, IA
Cataract Surgery

Syndee J. Givre, MD, PhD, Raleigh, NC
Neuro-Ophthalmology

Deeba Husain, MD, Boston, MA
Retina and Vitreous

Katherine A. Lee, MD, PhD, Boise, ID
Pediatric Ophthalmology and Strabismus

W. Barry Lee, MD, FACS, Atlanta, GA
Refractive Surgery; Optics and Refraction

Ramana S. Moorthy, MD, FACS, Indianapolis, IN
Ocular Inflammation and Tumors

Sarwat Salim, MD, FACS, Milwaukee, WI
Glaucoma

Elmer Y. Tu, MD, Chicago, IL
Cornea and External Disease

Focal Points Staff

Susan R. Keller, Acquisitions Editor

Kim Torgerson, Publications Editor

D. Jean Ray, Production Manager

Debra Marchi, CCOA, Administrative Assistant

Clinical Education Secretaries and Staff

Louis B. Cantor, MD, Senior Secretary for Clinical Education,
Indianapolis, IN

Christopher J. Rapuano, MD, Secretary for Ophthalmic
Knowledge, Philadelphia, PA

Dale Fajardo, Vice President for Education



This icon in text denotes additional content accessible in your digital module.



This icon in text denotes video content accessible in your digital module.

CONTENTS

Introduction	1
Historical Perspectives	1
Overview of IOL Specifications	3
IOL Materials	4
Biocompatibility	4
Light-Blocking Chromophores	6
Optical Clarity	6
Optic Opacification	6
IOL Design	7
Single-Piece Versus 3-Piece Design	7
Optic Configuration and Power	8
Aspheric Optics	9
Multifocal Design	10
Extended Depth-of-Focus IOLs	13
Complications of IOLs	13
Secondary Cataract Formation	13
Dysphotopsias	14
Conclusion	15
Clinicians' Corner	16
Suggested Reading	21

Focal Points Cumulative Index 1983–2014
www.aao.org/fpindex

The American Academy of Ophthalmology is accredited by the Accreditation Council for Continuing Medical Education to provide continuing medical education for physicians.

The American Academy of Ophthalmology designates this enduring material for a maximum of 2 *AMA PRA Category 1 Credits™*. Physicians should claim only the credit commensurate with the extent of their participation in the activity.

Claiming CME Credit: The American Medical Association requires that all learners participating in activities involving enduring medical materials complete a formal assessment before claiming continuing medical education (CME) credit. To assess your achievement in this activity and ensure that a specified level of knowledge has been reached, a post test for this module is provided. A minimum score of 80% must be obtained to pass the test and claim CME credit.

To claim *Focal Points* CME credits, visit the Academy web site (one.aao.org/CME-Central) to report CME credit you have earned. You can claim up to 2 *AMA PRA Category 1 Credits™* per module. CME credit may be claimed for up to three (3) years from date of issue.

Focal Points (ISSN 0891-8260) is published quarterly by the American Academy of Ophthalmology at 655 Beach St., San Francisco, CA 94109-1336. For domestic subscribers, print with digital 1-year subscription is \$205 for Academy members and \$245 for nonmembers. International subscribers, please visit www.aao.org/focalpoints for information about shipping charges. Digital-only 1-year subscription is \$165 for Academy members and \$205 for nonmembers. Periodicals postage paid at San Francisco, CA, and additional mailing offices. POSTMASTER: Send address changes to *Focal Points*, P.O. Box 7424, San Francisco, CA 94120-7424.

The Academy provides this material for educational purposes only. It is not intended to represent the only or best method or procedure in every case, nor to replace a physician's own judgment or give specific advice for case management. Including all indications, contraindications, side effects, and alternative agents for each drug or treatment is beyond the scope of this material. All information and recommendations should be verified, prior to use, with current information included in the manufacturers' package inserts or other independent sources and considered in light of the patient's condition and history. Reference to certain drugs,

instruments, and other products in this publication is made for illustrative purposes only and is not intended to constitute an endorsement of such. Some material may include information on applications that are not considered community standard, that reflect indications not included in approved FDA labeling, or that are approved for use only in restricted research settings. The FDA has stated that it is the responsibility of the physician to determine the FDA status of each drug or device he or she wishes to use, and to use them with appropriate informed patient consent in compliance with applicable law. The Academy specifically disclaims any and all liability for injury or other damages of any kind, from negligence or otherwise, for any and all claims that may arise out of the use of any recommendations or other information contained herein. The author(s) listed made a major contribution to this module. Substantive editorial revisions may have been made based on reviewer recommendations.

Subscribers requesting replacement copies 6 months and later from the cover date of the issue being requested will be charged the current module replacement rate.

©2015 American Academy of Ophthalmology®. All rights reserved.

LEARNING OBJECTIVES

Upon completion of this module, the reader should be able to:

- 1 Describe the design features of current IOLs
- 2 Articulate the current understanding of the role of ultraviolet (UV) and blue-blocking chromophores in IOL materials
- 3 Discuss recent advances in IOL technology designed to improve optical performance and patient satisfaction
- 4 Discuss the IOL features that reduce the risk of posterior capsule opacification
- 5 Recognize the symptoms of dysphotopsias, a common, typically transient side effect of IOL implantation

Introduction

Intraocular lenses (IOLs) represent what is arguably the greatest single advance in ophthalmology, bringing visual rehabilitation to millions of people following cataract surgery. Their impact is nothing short of amazing, as is the story of their invention by Sir Harold Ridley. In the 1940s, he discovered that shards of acrylic cockpit canopies remained inert in the eyes of a British pilot who was blinded when his aircraft crashed during World War II. Ridley developed and implanted the first artificial lens in November, 1949, and reported on the first 27 cases in 1952 (Figure 1). It was the first medical device implanted in a human being and generated considerable opposition from his peers.

Modern IOLs are taken for granted as safe and effective medical devices by the majority of people,

including the majority of ophthalmologists. It seems inconceivable today that patients would tolerate the unattractive, thick “Coke-bottle” spectacles of years ago, so named because the original containers of the Coca Cola beverage were curved glass bottles with thick, rounded bottoms. A diminishing number of ophthalmologists remember 10 days of bed rest followed by aphakic eyeglasses needed to correct the refractive error in the absence of the crystalline lens. Patients now expect almost immediate visual recovery with rapid return to full activities (Figure 2).

Historical Perspectives

Examining the current standard of IOLs is best done with the perspective of hindsight. Early IOL designs were primitive, and the techniques used to remove the cataract were equally primitive by today's standards. While risky surgery combined with early IOL design led to a tremendous number of complications, the numbers of successful implants eventually led to improvements in technology and technique. The earliest difficulties with IOLs were related to the surgical procedures of the day. Intracapsular cataract extraction (ICCE) removed both lens and capsule, leaving no capsule to support the IOL. Frequent complications of ICCE included corneal decompensation, retinal detachments, and cystoid macular edema (CME). The iris-clip and rigid anterior chamber lenses available at the time increased the rates of these complications and created additional ones such as uveitis-glaucoma-hyphema (UGH) syndrome (Figure 3). Provided the surgery allowed for anatomical success, a significant percentage of patients developed bullous keratopathy due to the relatively coarse nature of the procedure.

With the move to extracapsular cataract extraction (ECCE), the capsule was left intact, creating a more stable platform for IOL placement with less uveal contact. The IOL design advanced significantly with the innovation of the C-loop haptic by Dr. Robert M. Sinskey in 1981 (Figure 4), a modification of the Shearing J-loop

Financial Disclosures

The authors, reviewers, and consultants disclose the following financial relationships: Lisa B. Arbisser, MD: (C) Bausch + Lomb (2013, 2014); (L) Abbott Medical Optics (2014); (C, L, S) OptiMedica (2013). D. Michael Colvard, MD: (C) Abbott Medical Optics, Bausch + Lomb; (P) OASIS Medical (2011, 2012, 2015). Steven H. Dewey, MD: (C) Abbott Medical Optics; (P) Microsurgical Technology (2011–2015). Richard S. Hoffman, MD: (C) Carl Zeiss Meditec, Microsurgical Technology (2014, 2015). W. Barry Lee, MD, FACS: (C) Shire (2015); (L) Allergan, Bausch + Lomb (2013–2015); (P) Elsevier (2015). Eric Paul Purdy, MD: (L) Alcon Laboratories (2014). Sarwat Salim, MD, FACS: (L) Alcon Laboratories (2013, 2014), Merck &

Co. (2013). Elmer Y. Tu, MD: (C) Bausch + Lomb (2013); Seattle Genetics (2014, 2015).

The following contributors state that they have no financial interest or other relationship with the manufacturer of any commercial product discussed in their contributions to this module or with the manufacturer of any competing commercial product: Syn-dee J. Givre, MD, PhD; Deeba Husain, MD; Susan R. Keller; Katherine A. Lee, MD, PhD; Ramana S. Moorthy, MD, FACS; Kim Torger-son (2013–2015). Dasa Gangadhar, MD; Sharon L. Jick, MD (2013). Eric Paul Purdy, MD (2013, 2015). Ricardo G. Glikin, MD (2014, 2015). Lisa B. Arbisser, MD; Sarwat Salim, MD, FACS (2015).

C = Consultant fee, paid advisory boards or fees for attending a meeting (for the past 1 year)

E = Employed by a commercial entity

L = Lecture fees (honoraria), travel fees or reimbursements when speaking at the invitation of a commercial sponsor (for the past 1 year)

O = Equity ownership/stock options (publicly or privately traded firms, excluding mutual funds)

P = Patents and/or royalties that might be viewed as creating a potential conflict of interest

S = Grant support for the past year (all sources) and all sources used for this project if this form is an update for a specific talk or manuscript with no time limitation

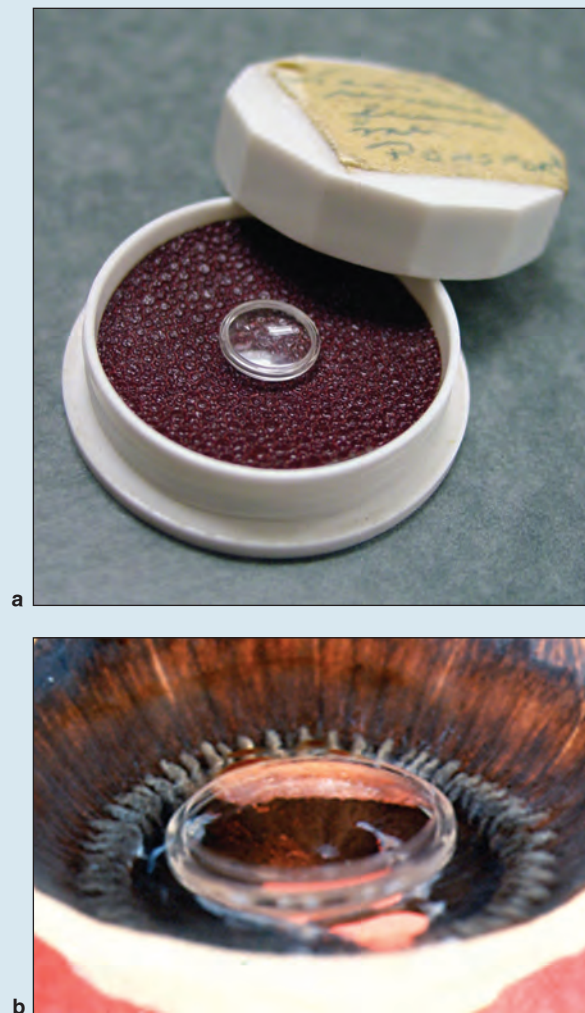


Figure 1 Ridley intraocular lens. **a.** The original Ridley intraocular lens in case, circa 1950, manufactured by Rayner. **b.** An oblique image of a Miyake-Apple specimen showing the Ridley IOL in situ. (Part **a** courtesy of the Museum of Vision and the American Academy of Ophthalmology. Part **b** from Springer and the original publisher *Der Ophthalmologe: Morphologische Befunde Menschlicher Autopsieaugen nach Implantation von Ridley-Intraokularlinsen* by J. M. Schmidbauer, 2001;98(11), reproduced with kind permission from Springer Science and Business Media.)

lens invented by Stephen P. Shearing in 1977 (Figure 5). Fixation entirely within the capsule was spotty, with only about one-third of IOLs implanted with both haptics in the bag. For lenses in the anterior chamber, the movement from closed-loop to open-loop design better preserved corneal endothelium (Figure 6). Improved manufacturing standards created more refined edges and surfaces. Sterilization techniques improved as methods using quaternary ammonium ions, ultraviolet radiation, and sodium hydroxide were discovered to be

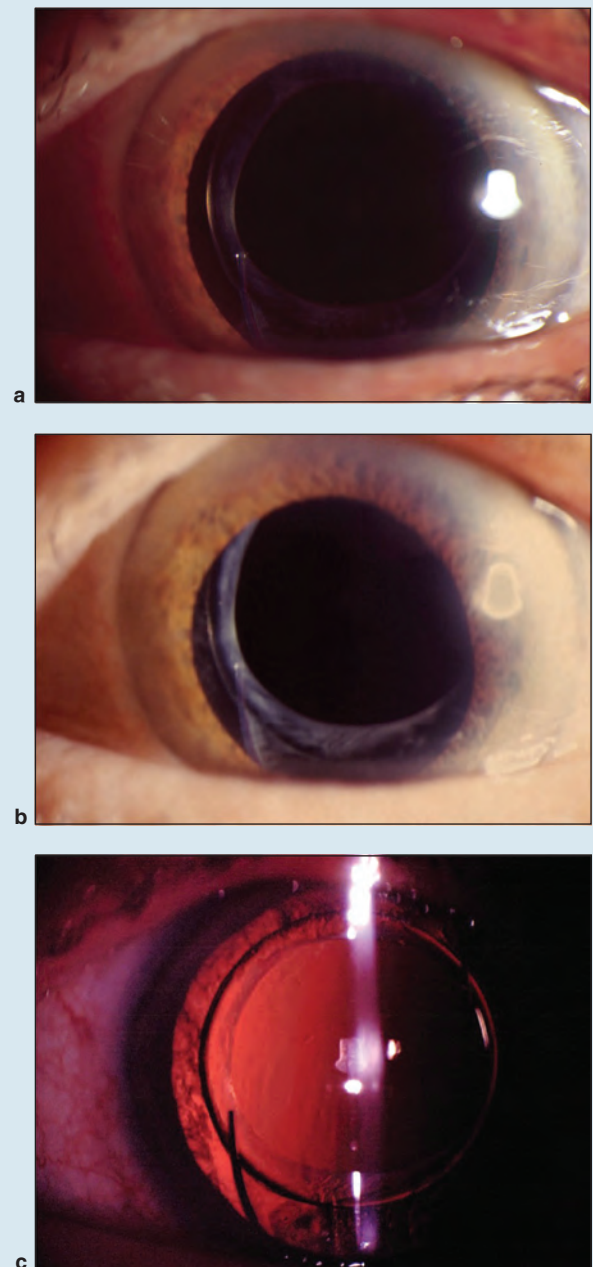


Figure 2 IOL lifespan. **a, b, c.** Since its invention in 1948, the IOL has become the most common human prosthetic device. Current IOL design standards in combination with meticulous surgical technique allow for visual restoration exceeding patient expectation. While the 5-year span represented in these clinical images is only a fraction of a patient's lifespan, there is no evidence to suggest that this result will not remain for several decades.

problematic. UGH syndrome and corneal decompensation rates declined.

Dr. Richard Kratz continued work on Dr. Charles Kelman's phacoemulsification system for cataract surgery during the 1970s. The invention of foldable IOLs




Figure 3 Leiske semi-flexible anterior chamber intraocular lens, circa 1978, manufactured by American Medical Optics. (Courtesy of the Museum of Vision and the American Academy of Ophthalmology.)




Figure 5 Style 500 J-loop intraocular lens, manufactured by CooperVision, Inc. (Courtesy of the Museum of Vision and the American Academy of Ophthalmology.)




Figure 4 Kratz Model 7251 intraocular lens, manufactured by Precision-Cosmet Co, Inc. (Courtesy of the Museum of Vision and the American Academy of Ophthalmology.)




Figure 6 Open-loop anterior chamber IOL. The Kelman-style open-loop IOL allowed for significant reductions in UGH syndrome, fostering an alternative means of IOL fixation in patients with compromised posterior capsules. (Courtesy of Liliana Werner, MD, PhD.)

by Dr. Edward Epstein in South Africa in the 1960s and 1970s and by Dr. Thomas Mazzocco in the United States in 1984 allowed for further improvement in surgical technique by helping to give rise to small-incision surgery in the late 1980s. Deformable IOLs could be inserted through smaller incisions, which led to lower rates of postoperative astigmatism and reduced wound-related complications.

Drs. Howard Gimbel and Thomas Neuhann provided a turning point in efforts to improve capsular fixation, which began in the early 1990s with the development of the continuous tear capsulotomy. The presence of a continuous capsulotomy fostered more reliable in-the-bag IOL implantation that allowed increased IOL

stability and improved centration. By improving the consistency of the anatomical result, the capsulorhexis improved outcomes in general and allowed for the evolution of IOLs to the present-day standards.

Overview of IOL Specifications

The safety and efficacy of IOLs depend on their design and the properties of the material from which they are made. Material used must be biocompatible, optically

clear, lightweight, durable, moldable, capable of being sterilized, resistant to forceps and folding marks, resilient to the stresses of implantation, able to withstand Nd:YAG laser capsulotomy, and inert in the eye through the rest of the patient's lifetime. The most common materials used today are foldable silicone and acrylic, as they can be implanted through a small incision. Polymethyl methacrylate (PMMA), less commonly used, is a rigid material suitable for rigid 1- and 3-piece IOL designs or for haptic materials.

IOL MATERIALS

All currently used IOL materials may be subdivided into hydrophobic (hydrophobic acrylic, silicone, and PMMA) and hydrophilic categories. Hydrophobic materials contain less than 2% water, compared to 18%–38% for hydrophilic materials. Table 1 summarizes specific types of IOLs, including the refractive index of each.

HYDROPHOBIC IOLS. The strength of the polymer backbone of the optic material determines its flexibility. Acrylics have a hydrocarbon backbone with pendant ester groups. PMMA is a homopolymer of methylmethacrylate. PMMA is the only nonfoldable optic material currently in use. PMMA has a refractive index of 1.49.

The co- and terpolymer materials contain a cross-linking agent to improve their elongation, tensile/tear strength, and resiliency. The percent of elongation at breaking point and tensile strength in pounds per square inch are critical in establishing the insertion characteristics of the lens, and thus ease of use, foldability through a small incision, resiliency during unfolding, post-incision resolution recovery, and stability in the eye.

Hydrophobic acrylic material has the unusual property of being tacky on the surface. Tackiness may help the lens adhere to the bag upon implantation but may cause it to stick to instruments or stick in the folded position for a prolonged period of time during implantation. The switch from folding forceps for IOL insertion to specifically designed inserters has alleviated many IOL insertion difficulties associated with hydrophobic acrylic materials.

Silicone material contains a polysiloxane backbone, methyl or phenyl alkyl groups and a cross-linker reinforcer. Silicone folds easily and springs open just as quickly. Acrylic material folds with greater resistance and unfolds slowly.

HYDROPHILIC ACRYLIC IOLS. These IOLs demonstrate high differences in water content. Originally manufactured from pure poly(hydroxyethyl methacrylic) acid (polyHEMA) and having a water content of 38%, these lenses were too easily deformed and opacified (calified), with a significant frequency. Current hydrophilic IOLs are copolymers of HEMA and PMMA, with water contents of 25%–26%, and are much more resistant to deformation and opacification. Hydrophilic acrylic

Table 1. Refractive Index of Selected Intraocular Lenses, By Material

LENS	MANUFACTURER	REFRACTIVE INDEX
Hydrophobic acrylic		
Tecnis acrylic	Abbott Medical Optics	1.47
PMMA	Many	1.49
enVista	Bausch + Lomb	1.54
AcrySof	Alcon	1.55
iSymm AF-1	Hoya Surgical Optics	1.55
Hydrophilic acrylic		
Softec HD	Lenstec	1.43
ACR6D	Corneal Laboratories	1.44
Collamer	Staar	1.45
Hydroview	Bausch + Lomb	1.47
Akreos AO	Bausch + Lomb	1.60
Silicone		
SofPort Advanced Optics	Bausch + Lomb	1.41
Staar Elastic Lens	Staar Surgical	1.41
Staar Elastimide Lens	Staar Surgical	1.41
Tecnis silicone	Abbott Medical Optics	1.46

IOLs are generally less expensive to manufacture. Given the range of water content, these lenses also comprise the most varied category of IOL materials.

BIOCOMPATIBILITY

IOL biocompatibility refers to the tolerance of the eye to the IOL; that is, it describes the interaction of the polymer with the host tissue and the mechanical impact of the IOL on the eye. Biocompatibility falls into two broad categories, uveal and capsular. Ophthalmologists are generally able to observe the macroscopic effects of the lens on ocular tissue, such as the fibrosis of the anterior capsule and cellular reaction in the anterior chamber. These findings are the cumulative result of the interaction of the IOL with either the lens epithelial cells (LECs) or the immune system.

UVEAL BIOCOMPATIBILITY. This refers to the reaction of the iris, ciliary body, and anterior choroid to the IOL. It is measured in rough terms by the deposition of foreign-body giant cells on the exposed surface of the optic. Surgical irritation to the anterior uvea causes inflammation-related changes in the blood–aqueous barrier. Monocyte and macrophage migration through the uvea blood vessel walls create foreign-body giant cell deposits on the IOL. Factors such as incomplete polymerization of the primary optic material during manufacturing or extrinsic contamination of the optic may lead to a potentially toxic reaction. Fortunately,

the current standards of manufacturing no longer make uveal biocompatibility an issue for most IOL materials. However, any IOL not placed in the capsule may have chafing due to continuous contact with the iris or ciliary body. This is particularly significant with square-edged single-piece acrylic IOLs. In 5-year studies involving uveitic patients, hydrophilic acrylic IOLs tend to be more uveal-biocompatible than hydrophobic acrylic or silicone IOLs.

CAPSULAR BIOCOMPATIBILITY. Capsular biocompatibility refers to how the material interacts with the lens capsule. A specific material may be compatible with LEC survival and result in less capsule fibrosis but greater cellular proliferation. Or if it is less compatible with LEC survival, fibrous metaplasia may be induced. The clinical desire for precise optical function requires a hybrid between these two states, in which the LEC activity is kept in balance between fibrosis and proliferation and the posterior capsule remains clear.

Compared to hydrophobic and silicone IOLs, hydrophilic acrylic materials have an increased tendency

for lens epithelial cell outgrowth onto the IOL surface, posterior capsule opacification (PCO), and capsular contraction.

Generally speaking, silicone IOLs are credited with a greater degree of fibrosis than hydrophilic or hydrophobic materials. Capsular contraction carries the risk of IOL decentration and axial shift and is of particular concern in patients with potential for compromised zonular support. Even if contraction of the anterior capsule opening does not impair visual acuity, the reduced opening can limit the examination of the peripheral retina and increase the difficulty of laser photocoagulation.

The design of an IOL can significantly alter the response of LECs even within the same material class. The observation that sharp-edged hydrophobic acrylic IOLs inhibited LEC migration led to research into sharp-edged optic designs intended to inhibit LEC migration. Studies comparing otherwise identical rounded-edged IOLs to sharp-edged IOLs show clear benefits to a sharp edge in reducing PCO, improved rotational stability, and reduced anterior capsule contraction (Figure 7). More recently, a specific rounded-edge silicone IOL (SI-40

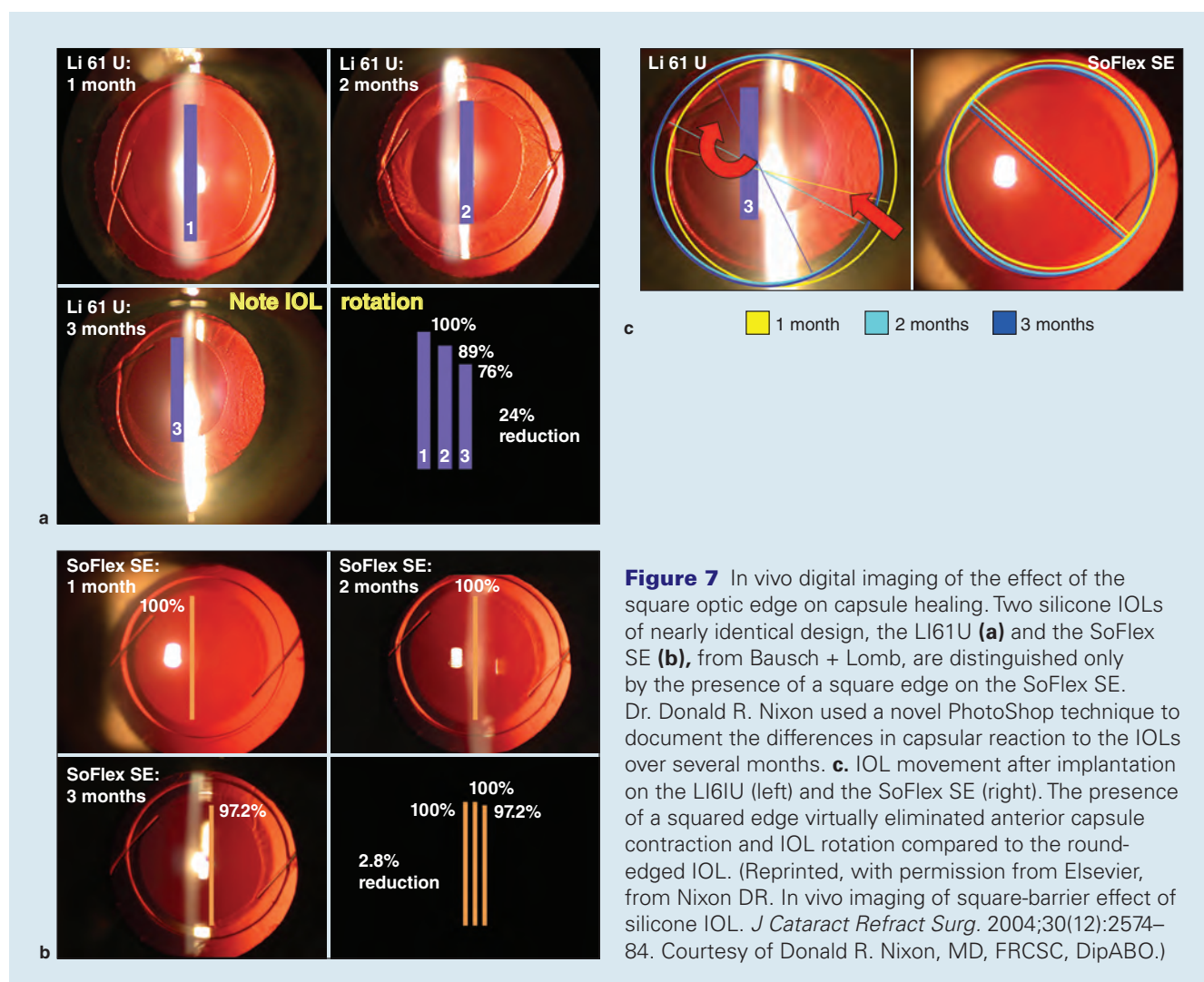


Figure 7 In vivo digital imaging of the effect of the square optic edge on capsule healing. Two silicone IOLs of nearly identical design, the LI61U (a) and the SoFlex SE (b), from Bausch + Lomb, are distinguished only by the presence of a square edge on the SoFlex SE. Dr. Donald R. Nixon used a novel PhotoShop technique to document the differences in capsular reaction to the IOLs over several months. c. IOL movement after implantation on the LI61U (left) and the SoFlex SE (right). The presence of a squared edge virtually eliminated anterior capsule contraction and IOL rotation compared to the round-edged IOL. (Reprinted, with permission from Elsevier, from Nixon DR. In vivo imaging of square-barrier effect of silicone IOL. *J Cataract Refract Surg.* 2004;30(12):2574–84. Courtesy of Donald R. Nixon, MD, FRCSC, DipABO.)

NB, Abbott Medical Optics [AMO], Santa Ana, CA) has been shown to reduce PCO more effectively than a sharp-edged hydrophobic acrylic IOL (MA60BM, Alcon, Fort Worth, TX) at 10 years after implantation. This suggests that the longest-term reduction in PCO is founded in mediating LEC activity through IOL material rather than IOL design alone.

LIGHT-BLOCKING CHROMOPHORES

Based on the original observation and recommendation of Dr. Martin Mainster in 1978, all IOLs available for implantation in the United States today contain an intrinsically bonded UV-blocking chromophore. The intent of these chromophores is to reduce damage to the retina from short-wavelength light in the UV range. As the human eye cannot detect UV light, the effect of these chromophores on vision is entirely undetectable.

The advent of UV-blocking was followed some years later by the addition of chromophores to block blue light. This was done by Hoya in Japan and Alcon in the United States in an attempt to reduce the risk of developing age-related macular degeneration (AMD). In vitro studies demonstrated the greater toxicity of light in the violet and blue spectra compared to longer wavelengths. Comparing an intense light both with and without a blue-blocking chromophore, the filtered light does not cause the same degree of damage in animal studies. While this study infers that blue-light blocking would have a protective effect, the highly artificial nature of the testing failed to simulate long-term, low-level exposure. As the range of color-blocking now falls within the visible spectrum, this specific reduction to the visible color spectrum has been highly controversial.

It is undeniably difficult to separate the complexity of a process such as AMD from a process as multifactorial as cataract surgery. Studies attempting to identify a relationship between cataract surgery and AMD performed in the 1980s and 1990s found conflicting results. Depending on the study, cataract surgery either posed a greater threat, providing a protective benefit, or was of no particular consequence. These studies were all hampered by design or sample size and did not serve to answer the very question they raised. Of particular significance, the studies included patients who had undergone older surgical procedures, including ICCE, and potentially received either no IOL, or IOLs predating UV-chromophore inclusion.

The Age-Related Eye Disease Study (AREDS) enrolled patients from 1992 to 2002, and prospectively evaluated patients at 6-month intervals until the completion of the study in 2004. Patients were enrolled if they demonstrated moderate AMD, and the primary study outcome has demonstrated a benefit in higher-dosage antioxidants in reducing AMD progression. During the course of the study, 1700 patients underwent cataract surgery, and 750 of these had AMD. Predating the inclusion of a blue-blocking chromophore, the

study found no demonstrable effect on the progression of AMD in these high-risk patients when compared to similar patients who did not undergo cataract surgery. This was the first study of its kind to have a prospective design protocol with significant number of patients, particularly patients specifically at risk for advancing AMD, and include patients undergoing modern surgical procedures and receiving UV-blocking IOLs.

It should be noted that a UV-blocking IOL without a blue-filtering chromophore allows more blue light than the natural human lens at any age. While blue light may play a role in some patients, there are multiple factors implicated in the development of AMD, including genetics, nutrition, smoking, circulation, angiogenesis, RPE lipofuscin, Bruch's resistance, and retinoid deficiency.

In addition, research into blue light and vision is evaluating the role of blue light in controlling circadian rhythms, sleep-wake patterns, mood and depression, pupillary response and melatonin metabolism. This is an area of intense research interest and should be followed carefully for new developments.

OPTICAL CLARITY

Light travelling through an optical system can be affected by any number of imperfections before it reaches its target. In the eye, light must pass through the irregularities of the tear film, aberrations of the cornea, and the aperture of the pupil prior to transmission through the IOL. Passing through the vitreous, and upon reaching the retina, the spacing of the photoreceptors becomes the limiting factor in resolving the transmitted image. In viewing a contrast grating, a theoretical limit of 120 cycles/degree has been postulated. That image then undergoes neural processing to provide the final acuity.

An ideal IOL should be optically superior to the crystalline lens removed at cataract surgery and not a limiting element in the image quality at the retina. The optical clarity of a given IOL design of a given material is measured by its modulation transfer function (MTF). MTF measures the ability of light to pass through an optical system with both resolution and contrast preserved. The higher the MTF value, the better the optical clarity.

In an optical bench study of 23 different IOLs, IOLs made of hydrophobic acrylic material with an asymmetrically biconvex profile showed the highest MTF. These tests are highly useful in determining how an IOL performs under ideal standardized bench conditions, but the weakness arises in the variability of the human system from patient to patient. Regardless, the typical MTF of all the materials tested exceeds the resolving capability of the human eye.

OPTIC OPACIFICATION

In broad terms, unintentional loss of IOL clarity is the result of either exogenous material deposition or of a failure in the manufacturing process. Severe

optic opacification may even necessitate IOL explantation. The most well-studied example of late opacification is the Hydroview (Bausch + Lomb, Bridgewater, NJ) hydrophilic acrylic IOL. Opacification developed 4–40 months after implantation and caused a decrease in visual acuity. Calcium precipitation was identified as the cause of granularity on the optical surfaces of 25 explanted Hydroview lenses.

In some instances, calcium deposits may be asymptomatic, as with surface deposits observed after implantation of ACR6D SE hydrophilic IOLs (26% water content) in 6 patients. Rarely, opacification in hydrophilic IOLs has been seen to reverse itself. Various proposals for the sporadic nature of hydrophilic IOL calcification include diabetes or uveitis in the recipient, asteroid hyalosis, and the specific use of certain ophthalmic viscosurgical devices (OVD) during cataract surgery.

A late form of opacification is also recognized as specific to PMMA lenses manufactured in the mid-1980s. Known as “snowflake” degeneration, white opacities in the central optic appear as the PMMA matrix degenerates.

Glistenings are a very frequent problem with certain specific hydrophobic acrylic IOLs, but can be seen to some extent in virtually all hydrophobic acrylic lenses, with the exception of the enVista acrylic IOL (Bausch + Lomb). During the manufacturing process, imprecise polymerization of the optic material results in microvoid formation within the optic material. The glistenings represent microscopic spheres of water that become trapped in these microvoids. While these glistenings are considered trivial by some, the visual impact has been well documented. The severity of glistenings has been related to the manufacturing procedure (finding greater numbers of glistenings in injection-molded IOLs than in lathe-cut IOLs), packaging, and temperature fluctuation. Glistenings are known to increase over time (Figure 8).

IOL Design

SINGLE-PIECE VERSUS 3-PIECE DESIGN

IOLs come in two major design varieties, single-piece and 3-piece. Single-piece IOLs are crafted from a single piece of material with the haptics intrinsically attached to the optic. Three-piece lenses have the optic manufactured separately from the haptics with the haptics then implanted into the optic material. Haptics may extend from the optic at various angles, usually between 0°–10° of angulation. Haptics play a role in the position of the IOL after implantation.

The first single-piece IOLs were the plate-haptic silicone lenses manufactured by Staar Surgical (Monrovia, CA). These lenses are relatively short in length at 10.8–11.2 mm in diameter. They are designed for in-the-bag placement only.

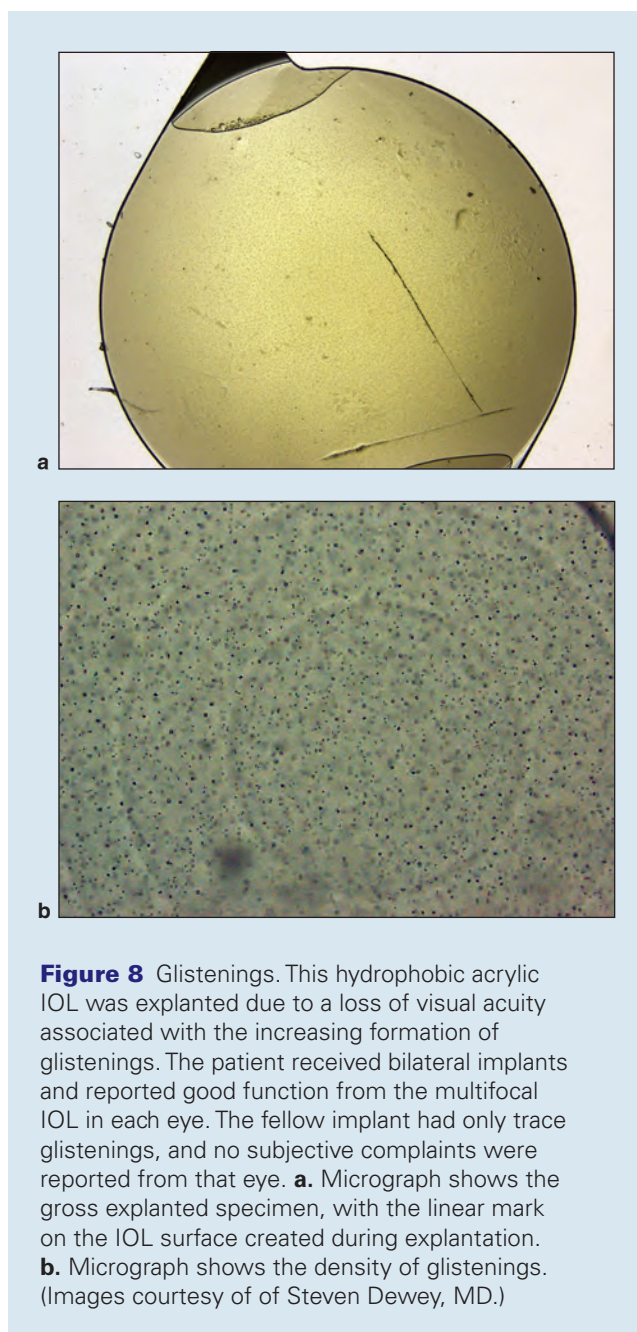


Figure 8 Glistenings. This hydrophobic acrylic IOL was explanted due to a loss of visual acuity associated with the increasing formation of glistenings. The patient received bilateral implants and reported good function from the multifocal IOL in each eye. The fellow implant had only trace glistenings, and no subjective complaints were reported from that eye. **a.** Micrograph shows the gross explanted specimen, with the linear mark on the IOL surface created during explantation. **b.** Micrograph shows the density of glistenings. (Images courtesy of Steven Dewey, MD.)

More recent single-piece IOLs are crafted from hydrophobic or hydrophilic acrylic materials, and they superficially resemble their 3-piece counterparts (Figure 9). As the material has a high degree of compressibility, the outward force of the haptic on the capsular bag is negligible but serves to stabilize the optic in the desired capsular location during the process of capsule contraction. Given the relatively delicate nature of the acrylic material with regards to shearing, the haptics are generally bulky and demonstrate an excellent rotational stability. All current single-piece foldable IOLs have square posterior edges that also contribute substantially to the general lack of postoperative rotation.




Figure 9 AcrySof single-piece hydrophobic acrylic IOL (Alcon Laboratories). In this pair of cadaver-eye micrographs, perfectly positioned single-piece hydrophobic acrylic IOLs reside within the capsular bag. The whitish material represents regenerating cortex, which would have grown to form Soemmering ring. **a.** Very thorough cortical removal was achieved, and very little cortical regeneration has taken place. **b.** A capsule with a greater degree of regenerated cortex indicating possibly poorer cortical removal, or much more likely, a greater passage of time between IOL implantation and specimen collection. While this design has several advantages over traditional 3-piece IOLs, placement of this lens outside of the capsular bag can result in uveal chafing, with pigmentary glaucoma and recurrent hyphema as potential complications of a malposition.

Three-piece foldable IOLs have haptics of a much more rigid material, such as PMMA or polyamide. These haptics have considerable outward compression force compared to that of single-piece foldable IOLs. The haptics are much thinner and are much better tolerated in the sulcus than the bulky, single-piece haptics. These haptics are much easier to damage during IOL insertion, and recent reports associate 3-piece IOLs with greater degrees of tilt as a result.

Overall IOL length from haptic to haptic is generally 13 mm for 1-piece IOLs, but may be shorter in a 3-piece lens. In cases of capsule compromise in which the 3-piece IOL is to be placed in the sulcus without optic capture through the capsulorhexis, it is generally accepted that 13 mm is the minimum haptic length to achieve stable sulcus fixation. While it is generally considered that sulcus diameter will correlate to the white-to-white corneal diameter, this is not always the case and larger IOL length may be needed. In the United States, only the rounded-edge, silicone Staar AQ series IOLs have haptic lengths greater than 13 mm.

Two clinical situations arising specifically as a complication of IOL placement are capsule phimosis and late within-the-bag IOL dislocation. These frequently occur together in the same eye, and many of the affected patients will demonstrate pseudoexfoliation. Each condition can occur even in the presence of a capsular tension ring, and aspects of IOL material and haptic design to reduce these problems continue to be an area of research. In general, if a patient is considered to be at risk of capsule phimosis or late IOL-bag dislocation, silicone lenses should be avoided. Consideration should be given for 3-piece lenses with the haptics in the sulcus and optic captured in the capsulorhexis.

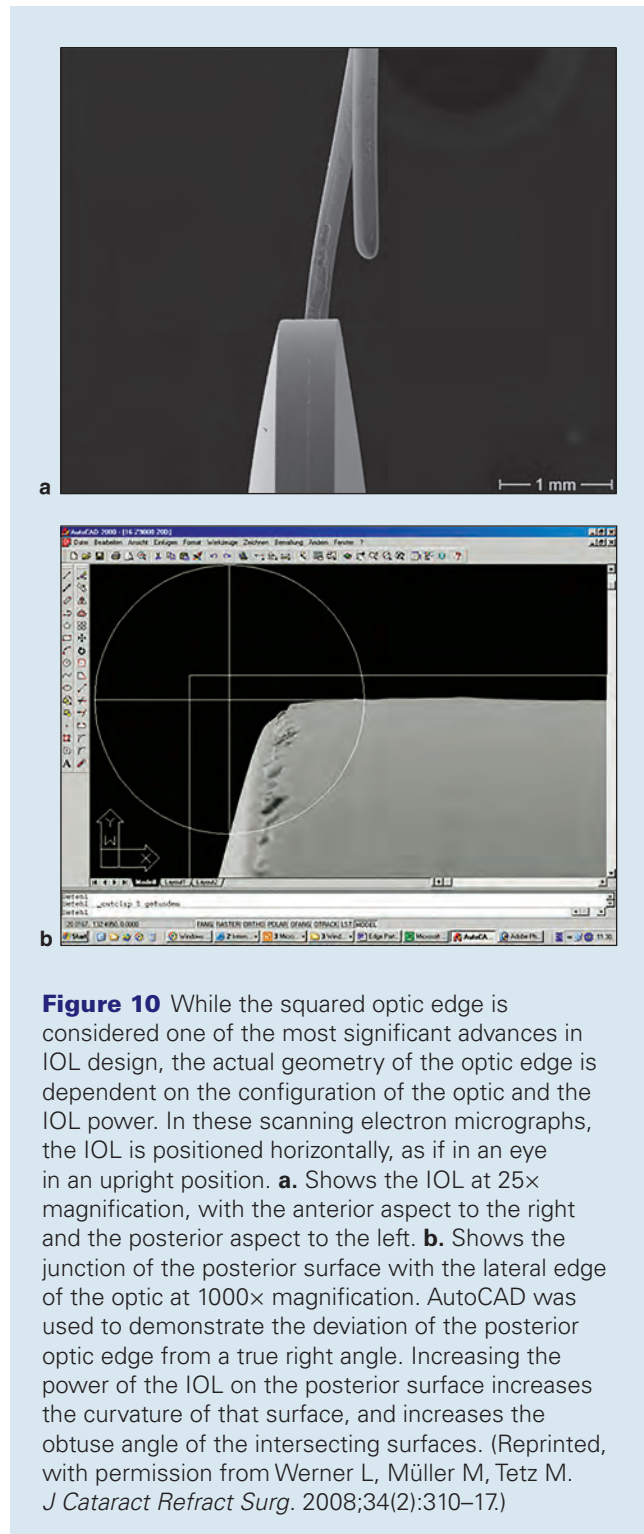
As mentioned previously, the sharp-edged haptics of a single-piece IOL can cause significant uveal chafing with concomitant pigment dispersion, uveitis, hyphema, and glaucoma. The only single-piece IOL designed for sulcus placement is the Sulcoflex, manufactured by Rayner (East Sussex, UK), and is currently unavailable in the United States.

OPTIC CONFIGURATION AND POWER

Optic size is most commonly 6.0 mm, and considerably less than a millimeter in thickness. There are theoretical advantages to varying optic size. As the optic contributes to the greatest bulk of the IOL, by reducing the diameter of the optic, the IOL can be made smaller to be inserted through a smaller incision. However, a smaller diameter optic increases the likelihood of optical phenomena such as glare and haloes, a problem made worse with larger diameter pupils, but not improved necessarily by larger diameter IOL optics.

The optic bears the IOL power that is determined by the radius of curvature and the index of refraction. In manufacturing, it is simpler to vary the IOL power by changing only one surface of the IOL, leaving the other surface constant. The balance of power on the surface of the optic describes its configuration. The term *biconvex* refers to IOLs that have the power generally equally distributed on the anterior and posterior surfaces. *Planoconvex* or *convex-plano* refer to lenses with one surface having no power at all. Lenses with a plano or low-power anterior surface leave a reflective, almost ghost-like appearance to the pupil under certain lighting

conditions. While useful in certain circumstances, such as placement in the case of retained silicone oil, IOLs with a plano surface have largely been abandoned due to their increased relative optic thickness. The power and configuration of the IOL in combination with its material will also determine the true “sharpness” of the posterior edge (Figure 10).



Note that labeled IOL powers are, in reality, only a close approximation of the actual IOL power based on the planned final placement of the lens. For example, an 18.50 D labeled lens for posterior capsule placement may actually be 18.20 or 18.80 in dioptric power, depending on the manufacturer’s standards within the FDA’s labeling guidelines. Variability in IOL power is not the only determinant of refractive outcome, as placement of the IOL in the sulcus will increase the effective power of the IOL and leave a myopic result compared to the intended result. Preoperative estimation of IOL position, postoperative refraction estimation, and preoperative corneal power as well as axial length determination and pupil size are among the sources of error that affect refractive outcome.

ASPHERIC OPTICS

Spherical aberration occurs when peripheral light rays and axial light rays come to different foci, which causes images to appear blurred. This results in a decrease in contrast sensitivity. While loss of contrast sensitivity may not be identified on a standard Snellen acuity chart, loss of contrast will affect functional vision (eg, how well people see in less-than-optimum lighting conditions). In 2004, the Tecnis silicone IOL (Abbott Medical Optics) was the first lens approved by the FDA to feature aspheric optical correction. This feature is now offered in lenses from Alcon, Bausch + Lomb, Hoya, Rayner, Zeiss, and virtually every other IOL manufacturer.

Spherical aberration is positive when the peripheral light rays focus anterior to the axial light rays. The aspheric lens design is intended to correct the positive spherical aberration of the cornea. In the young eye, negative spherical aberration of the young crystalline lens balances the positive spherical aberration of the cornea. With age, the spherical aberration of the crystalline lens becomes more positive and the lens no longer compensates for corneal spherical aberration.

Traditionally, spherical IOLs were made with a positive spherical aberration adding to corneal spherical aberration and reducing functional vision. Early attempts to correct for spherical aberration were disrupted by the relatively inconsistent surgical results of the day. The Tecnis IOL (Figure 11) is negatively aspheric with a modified prolate surface, and is designed to correct 27 microns of spherical aberration. As the first lens to correct spherical aberration, the Tecnis provided statistically and functionally significant improvements in contrast sensitivity relative to the spherical controls, and enhanced functional vision under both mesopic and photopic conditions. The AcrySof (Figure 12) aspheric lens (Alcon) is designed with 18 μ m of negative spherical aberration to compensate for the positive spherical aberration of the cornea; contrast sensitivity testing showed equivalence with the spherical monofocal control subjects. Most patients undergoing cataract surgery



Figure 11 The hydrophobic Tecnis single-piece IOL is transparent with an optic incorporating negative spherical aberration to improve contrast sensitivity. (Courtesy of Abbott Medical Optics.)




Figure 12 The hydrophobic AcrySof single-piece IOL contains a yellow chromophore with an optic incorporating negative spherical aberration to improve contrast sensitivity. (Courtesy of Alcon Laboratories.)

will potentially benefit from a negatively aspheric IOL. Patients who have undergone myopic LASIK or PRK have greater amounts of positive corneal spherical aberration and will benefit from these aspheric designs.

The SofPort AO lens (Bausch + Lomb) is designed to be simply aspheric, thus neither correcting nor worsening

spherical aberration attributable to the IOL. The advantage of a neutral aspheric lens is the lack of visual degradation associated with IOL decentration or tilt. Decentered IOLs with an aspheric correction will induce coma to varying degrees. Neutral aspheric IOLs can be decentered without degrading contrast sensitivity. These lenses are suitable in cases of previous refractive surgery in which the corneal correction was off-center, or if the patient has a naturally neutrally aspheric cornea.

While it would seem that there is no longer a benefit from a simple spherical IOL, positive asphericity is useful in reducing optical aberrations in patients who have undergone hyperopic LASIK or PRK.

As spherical aberration is highly varied in the population, and does not correlate with keratometry or a corneal Q value, the best method of selecting an aspheric IOL for a given patient is by specifically measuring corneal aberration with topography. Research continues as to the ideal residual value of spherical aberration as small amounts are felt to convey some depth of field.

MULTIFOCAL DESIGN

Assuming little residual astigmatism is present, monofocal intraocular lenses correct vision at one focal position—either near, intermediate, or distance. Bifocal and multifocal intraocular lenses direct light to two or more focal points. Three examples of multifocal design are diffractive optics, as exemplified by the Tecnis multifocal IOL (Figure 13a, b); refractive optics, as seen with the ReZoom multifocal lenses (Abbott Medical Optics; Figure 14) and a combination of apodized diffractive optics, as seen with the AcrySof ReSTOR (Figure 15) multifocal IOL.

While the technology behind each of these lens designs is highly sophisticated, the fundamental principle is one of compromise. In particular, multifocal lenses demonstrate reduced contrast sensitivity compared to their current aspheric monofocal counterparts. This is due to the division of light between the focal points, and the loss of some focused light due to blend zones or diffractive optics. Patients to be considered for these IOLs must display pristine ocular health to fully appreciate the benefits of the technology. Even under the best of circumstances, a significant number of patients will have extraneous light images that do not improve over time.

Refractive optics were the first to be FDA-approved and are found on the Array (Abbott Medical Optics) and ReZoom multifocal lenses. Concentric wave-like rings, or zones, provide simultaneous near and distance vision in alternate zones and the aspheric transition between the zones provides intermediate vision. The near add is +3.50 D at the IOL plane, which is +2.85 D at the spectacle plane. This multifocal design has lost considerable favor over time due to the increased problem with halos compared to a diffractive-style multifocal.

Diffractive optics, as seen with the Tecnis lenses, distribute the incoming light to approximately 50% near




Figure 13 Tecnis multifocal IOL. **a, b.** The Tecnis diffractive multifocal IOLs are designed to function at near and distance independent of pupil size. (Courtesy of Abbott Medical Optics.)



Figure 14 The ReZoom refractive multifocal IOL. (Courtesy of Abbott Medical Optics.)

and 50% far foci at virtually all pupil diameters. However, some light is lost due to the nature of the diffractive process. The three different models have optical power adds of 4.00 D, 3.25 D and 2.75 D on the posterior surface of the optic. These adds correspond to 3.00 D, 2.40 D, and 2.00 D at the spectacle plane.

An apodized diffractive optic, as found on the ReSTOR lens, merges a diffractive optic on the anterior optic surface within the 3.6 mm center to distribute the incoming light equally to near and far foci and a refractive ring around this center to direct light to distance



Figure 15 The apodized optic of the ReSTOR balances the need for near vision with a refractive aspect designed to improve distance performance. (Courtesy of Alcon Laboratories.)

vision. The add powers are 4.0, 3.0 and 2.5 on the optic, resulting in adds of 3.2, 2.5 and 2.0 diopters, respectively, at the spectacle plane.

ACCOMMODATIVE DESIGN. While multifocal lenses provide a significant benefit for near and intermediate vision for select patients, they do not restore accommodation. Some patients receiving monofocal lenses achieve a balance between distance and near vision, but this achievement is sporadic and typically regarded as the result of optical aberrations that result in pseudoaccommodation. Forward movement of a nondeformable optic or change in curvature of a deformable optic could achieve the goal of accommodation. Unfortunately, a full millimeter of movement in an average eye will only yield about 1.30 D of near power, with higher-power lenses in shorter eyes giving better results, and lower-power lenses in longer eyes giving worse results.

A truly accommodating lens design has yet to be developed, but a number of designs emulate features of accommodation to provide varying degrees of near vision. While many of these are undergoing the FDA approval process, the first IOL to receive an FDA indication for accommodation is the Crystalens (Bausch + Lomb; Figure 16). The original design was conceived by Dr. J. Stuart Cumming, who noted that plate haptic silicone lenses seemed to have a higher likelihood of pseudoaccommodation than standard 3-piece IOLs. He proposed that the plate lenses rest further posteriorly in the capsule, and the flexing of the IOL forward within the capsule allowed the improved near function.

Alternative IOL designs to mimic accommodation include dual optic IOLs and fluid-filled IOLs. While



Figure 16 The Crystalens is the only FDA-approved IOL to treat loss of accommodation. This modified plate-haptic lens is designed to flex with contraction of the ciliary body, increasing the effective lens power and thus near function. (Courtesy of Bausch + Lomb.)

showing great promise through any number of testing parameters, these designs are not available in the United States.

TORIC IOL DESIGN. Forty percent of patients undergoing cataract surgery will have one or more diopters of pre-existing corneal astigmatism. Cataract surgery with a simple monofocal IOL will treat astigmatism existing within the lens, but will not treat astigmatism at the level of the cornea. Prior to the advent of current small-incision phacoemulsification, highly variable amounts of astigmatism would be induced by cataract surgery, with the potential for increasing amounts of against-the-incision astigmatism developing years following surgery.

Correction of astigmatism is performed to decrease the dependence on spectacles. Small-incision phacoemulsification is generally regarded as being astigmatismally neutral, with the smaller incision size inducing the least amount of astigmatism by causing the least amount of corneal flattening in the meridian of the incision. By understanding the magnitude and axis of preoperative astigmatism, either corneal or limbal incisions can be placed to decrease the magnitude of astigmatism after cataract surgery, or the main cataract incision itself can be modified to achieve the desired effect.

The first FDA-approved IOL to correct pre-existing corneal astigmatism at the IOL plane was the Staar Toric IOL (Staar Surgical, Monrovia, CA; Figure 17a). This plate-haptic silicone IOL has hash marks at the periphery to align the orientation of the astigmatism

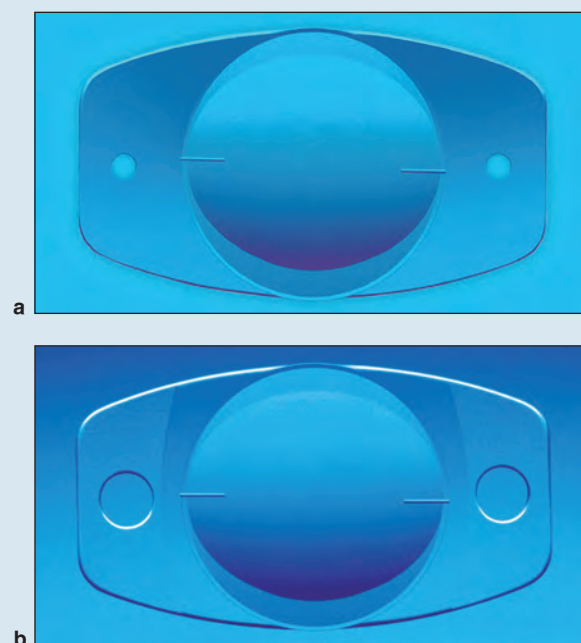


Figure 17 Staar toric plate haptic IOL. **a.** Original design with shorter haptic length and smaller fixation holes. **b.** Improved design with larger fixation holes and longer overall length. The improved design significantly improved rotational stability, and thus astigmatic correction. (Courtesy of Staar Surgical.)

correction. Early designs of this lens had smaller holes in the plate-haptic, and rotation and decentration were relatively common. Larger holes in the haptic created greater areas of capsule apposition and improved these issues considerably (Figure 17b).

The single-piece hydrophobic acrylic AcrySof toric IOL received FDA approval in 2005 (Figure 18). The original lens treated astigmatism up to 3.00 D at the corneal plane. It was subsequently expanded to cover up to 4.50 D and modified to incorporate aspheric optics in 2009. More recently, the Tecnis single-piece hydrophobic acrylic received FDA approval and treats astigmatism up to 2.75 D of corneal astigmatism. Both the AcrySof and Tecnis lenses have marks at the junction of the optic and haptic to allow for intraoperative alignment.

Another single-piece silicone plate haptic IOL incorporating toric correction is the Trulign Toric IOL (Bausch + Lomb). Based on the Crystalens design, this IOL treats up to 2.75 D at the corneal plane and has the advantage of offering a broader range of vision.

Toric IOLs, in general, create new challenges for implantation compared to standard monofocal IOLs. While planning the correction of pre-existing astigmatism has always been important, understanding how the surgical incision affects astigmatism becomes even more important. Next is the measurement of the pre-existing

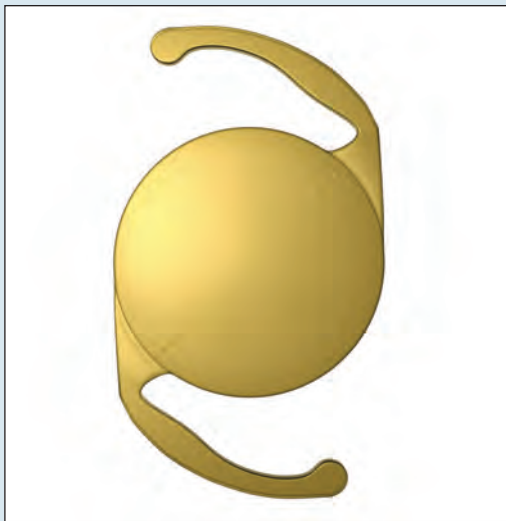


Figure 18 The hydrophobic acrylic Alcon Toric IOL currently corrects up to 4.50 D of astigmatism at the spectacle plane, and comes in a spherical as well as an aspheric design. Note the marks along the plus axis of cylinder correction. (Courtesy of Alcon Laboratories.)

corneal astigmatism with reference to axis and magnitude. A number of devices have demonstrated efficiency at this, but no device is considered perfect. Obviously, the more accurately the cornea can be measured, the more accurately it can be treated.

Calculating the specific IOL to be used is more challenging. Within the power of the IOL to be used, the range of IOL choices varies from 2 (Staar plate haptic IOL) to 7 (AcrySof IQ Toric), depending on the magnitude of the astigmatism. Factoring in the effect of the cataract incision and the effect of any additional relaxing incisions will alter the choice.

Preoperatively and intraoperatively, aligning the axis of corneal astigmatism with the axis of the IOL becomes paramount. Typically, in the preoperative area, markings are made on the limbus that will allow alignment of the axis marker later in the surgical field. The axis markings on the IOL are then properly positioned within the confines of an intact capsular bag and only with an intact capsulorrhexis. Parallax error must be accounted for, and the IOL should be centered on the visual axis.

Factors affecting the final alignment of the IOL include the accuracy of the preoperative marking and intraoperative alignment, the thoroughness of OVD removal during surgery, and the patience of the surgeon in allowing the IOL to completely unfold and the haptics to unfurl. A toric IOL loses approximately 10% of its effect for every 3° of rotation off-axis. While this means a rotation of 30° is necessary to negate the toric effect of

the IOL, a rotation of 10° or more will degrade the optical function enough to warrant repositioning.

Intraoperative devices for measuring toric IOL placement accuracy are gaining popularity, as well as devices for calculating the corrective steps needed to alter the position of a misaligned lens. Femtosecond-laser assisted cataract surgery also offers to improve the accuracy of incisional astigmatism correction, but appears to be limited to 2.00 D of effect. There are currently no 3-piece or sulcus-based treatments for corneal astigmatism available as an IOL option.



Insertion of Single-Piece Silicone Plate Haptic IOL Incorporating Toric Correction
(01 min 25 sec)

EXTENDED DEPTH-OF-FOCUS IOLS

The quest for restoring vision to youthful levels is continuing to drive innovative thinking. At the time of this publication, two different IOLs were being developed outside of the United States, by Abbott Medical Optics and Hoya. The premise of these lenses is somewhat contradictory to prevailing thought in that spherical aberration is specifically induced to extend the depth of focus of the IOL. In addition, the Abbott lens, branded as the “Symfony,” further enhances acuity by reducing chromatic aberration through a diffractive gradient on the IOL surface.

Neither lens claims to restore near vision to the levels of accommodation necessary to function fully spectacle-free, but rather to enhance the intermediate vision well above the performance of standard aspheric monofocals. The advantages of each lens include the simplicity of insertion, as they are both built upon the standard monofocal IOL platform, and the reduction in night glare associated with multifocal design. As with any new innovative IOL, any drawbacks will be discovered with greater widespread use, but the theoretical limitations of these lenses are exceptionally low.

Complications of IOLs

SECONDARY CATARACT FORMATION

With the preservation of the posterior capsule as the point of support for the IOL within the eye came a new complication of cataract surgery—posterior capsule opacification (PCO). Early surgical options to treat this condition were inelegant to say the least. Truly revolutionary, the treatment of PCO using a YAG laser was first performed by Daniele S. Aron Rosa in 1979. This simple and elegant treatment offered the alteration of an anatomical structure within the eye without the risks associated with incisional surgery by disrupting the opacified posterior capsule through the IOL itself using the power of focused and amplified light.

With capsular support of the IOL, PCO was generally considered an inevitable consequence of cataract surgery. By the mid-1990s, progress in cataract surgical technique established that a continuous tear capsulotomy with thorough cortical clean-up and in-the-bag IOL placement was achieved routinely. At the same time, the first hydrophobic acrylic IOL, the AcrySof MA60BM, was approved by the FDA in 1994. The double-square edged IOL design was not considered at the time to be of significance, but concurrent observations showed decreases in rates of PCO that were remarkable compared to the standards of the day.

In efforts to reduce PCO, research by Dr. David Apple, Dr. Okihiro Nishi, and Dr. Rupert Menapace, among others, has focused on surgical technique, IOL edge design, and IOL material. The overall effect is the formation of a fibrotic bend of the capsule at the posterior edge of the optic that inhibits migration of LECs into the area of the visual axis. Today, virtually every IOL sports the posterior square edge as a barrier to lens epithelial cell proliferation across the posterior capsule (Figure 19). By incorporating the correct surgical technique and by using an IOL with appropriate design features, decreased rates of PCO within the first three to five years after surgery have now become commonplace.

While reduction of early-phase PCO saw delays in the need for YAG-laser capsulotomy, the very nature of LECs allowed for late proliferation that would eventually result in PCO in around one-third of patients. Referred to as Soemmering ring, a layer of residual lens epithelial cells at the periphery of the capsule continues the process of regeneration. With time, the peripheral capsule inflates with regenerated cortical material, much as a child's swim ring becomes inflated with air. The effect of the regenerated cortex remodels the fibrotic capsular bend and, in some cases, allows regenerating LECs to breach this structure and spread across the posterior capsule. This process may result in symptomatic PCO several years following surgery.

Elimination of the posterior capsule seems to be the only certain way to reduce the rate of capsule opacification. First described by Dr. Howard Gimbel as a means of converting a posterior capsule tear to a posterior capsulorrhexis, the intentional opening of the posterior capsule is performed to capture the optic posterior to the posterior capsule, essentially in the Berger space. Dr. Marie Tassignion designed a lens specifically to be captured in the anterior and posterior capsule openings, termed the “bag in the lens” design. The surgical challenges of creating the opening in the posterior capsule without concomitant vitreous loss has slowed progress in this arena, but may be invigorated by the precision of the femtosecond laser.

DYSPHOTOPSIAS

An unintended consequence of every IOL is the creation of unwanted light images. Termed *dysphotopsias*, these

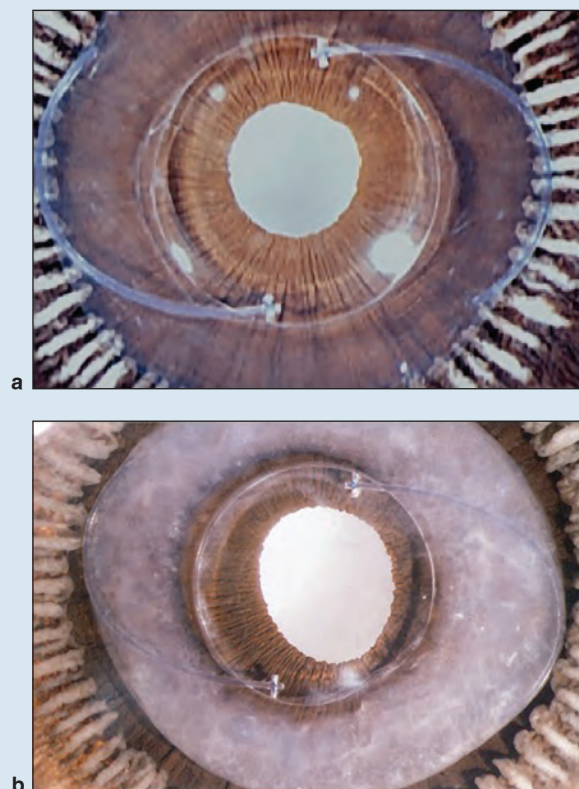


Figure 19 Soemmering ring formation and the AcrySof MA60BM (Alcon Laboratories). This AcrySof 3-piece hydrophobic acrylic IOL was the first foldable hydrophobic acrylic IOL available in the United States. It had a squared optic edge. **a.** The cortical clean-up was meticulous and, quite likely, very little time passed between IOL implantation and specimen collection as evidenced by the absence of regenerated cortex. **b.** Nearly complete cortical regeneration is observed surrounding the optic, likely taking years to develop (compare to Figure 9). The interaction of material and design within the capsule resulted in an effective barrier to lens epithelial cell migration. Despite the florid regenerated cortex present at the optic edge, posterior capsule opacification was averted for this patient.

images are highly sporadic in nature, being inconsistent from patient to patient and IOL to IOL. As the absolute cause of these unwanted images remains elusive, when they persist, they are difficult to eradicate.

Dysphotopsias are divided into those involving bright flashes (positive dysphotopsias) and those involving dark areas (negative dysphotopsias). Positive dysphotopsias have been associated with a truncated IOL edge. First publically discussed by Dr. Samuel Masket in association with a 5 × 6 mm optic PMMA IOL in the early 1990s, these flashes are typically transient in nature, occurring only in the presence of a light source obliquely aligned with the patient's IOL.

They are most commonly temporal but can be central as well.

Negative dysphotopsias were first described by Dr. James Davison as a “horse-blinder” effect. As these are almost exclusively temporal, early theories focused on the temporal incisions, the most common location, with clearing edema at the incision as the rationale behind the resolution of the issue.

Both types of dysphotopsia are seen under the condition of an otherwise “perfect” uncomplicated cataract surgery, and are frequent during the first month, affecting around 20% of patients, and. Both fortunately diminish almost completely for most patients during this period.

In evaluating patients who continue to experience dysphotopsias past 6 months, several factors appear to come forward. Primary is the higher index of refraction. The higher the index, the more effectively the light rays are bent within a thinner optic. This presents the quandary that a smaller incision affords less induced astigmatism, but the cost of the smaller incision is a thinner optic with a higher index of refraction.

The next factor is the truncated IOL edge, reducing the rate of PCO. Ray-tracing diagrams quite easily satisfy the optical effect of a stray light source reflecting internally off the square edge of the IOL. The truncated square edge holds advantages both from an individual’s point of view—decreased rates of capsule opacification—as well as a public health perspective—decreased procedure costs over time as a result of fewer YAG capsulotomies performed.

Manufacturers have responded to these issues by devising treatments for the IOL edge. Frosting an IOL edge diminishes the reflectivity of the edge itself. This has the benefit of reducing the magnitude of positive dysphotopsias, but does not alter the configuration of the optic or the index of refraction. A hybrid posterior squared-edge combined with an anterior rounded-edge (OptiEdge, Abbott Medical Optics) was conceived by Dr. David Apple. This design diminishes the area of the truncated edge, and as a result, diminishes, but does not eliminate dysphotopsias.

Treatment of the remaining unwanted images is based on educated speculation as to the cause. Positive dysphotopsias have been best treated by IOL exchange

and piggyback IOL placement. Success in elimination of the symptoms is best when the new IOL has rounded, less truncated edges and lower refractive index.

Speculation persists as to the etiology of negative dysphotopsias. Ray-tracing studies show that IOLs create a ring scotoma due to the higher constant index of refraction (1.44–1.55) compared to the varying refractive index of the natural lens (1.36–1.40), which changes from center to periphery. The ring scotoma is present for 360°, but due to the effects of the nasal bridge and orbital rim, is only visible temporally. However, patients with persistent symptoms rarely have resolution from an IOL exchange, regardless of how the second IOL configuration and material differs from the first. This has led to the idea that the anterior capsule overlying the edge of the optic is a contributing factor, and symptomatic patients have been improved by either YAG excision of the anterior capsule, or by reverse optic capture.

Whether the patient’s acclimation to dysphotopsias is driven by the fibrosis occurring at the edge of the IOL within the capsular bag or whether neuroadaptation simply dampens the magnitude of the image over time is not known. The location of the incision may have some role in the early symptoms; however, this is not thought to be a significant contributing factor in patients with persistent symptoms.

Conclusion

While the perfect IOL has yet to be designed, huge strides have been made since the introduction of Harold Ridley’s first IOLs. Surgeons make their choices based on ease of handling and implantation, the biophysical impact of lens and ocular tissues, marketing approval status, and current research. Patients benefit from rapid visual rehabilitation and, with few exceptions, can expect to enjoy a lifetime of functionally enhanced vision as a result.

Steven Dewey, MD, is a practicing ophthalmologist at Colorado Springs Eye Clinic, P.C., Pinnacle Eye Center, in Colorado Springs, Colorado.

Clinicians' Corner

Clinicians' Corner provides additional viewpoints on the subject covered in this issue of *Focal Points*. Consultants have been invited by the Editorial Review Board to respond to questions posed by the Academy's Practicing Ophthalmologists Advisory Committee for Education. While the advisory committee reviews the modules, consultants respond without reading the module or one another's response. –Ed.

1. What is your preferred intraocular lens (IOL) design for a "routine" patient with no outside factors such as previous LASIK surgery or other ocular issues?

>>>Dr. Glikin: In these cases, I use an acrylic hydrophilic, single-piece IOL, the Auroflex FH5600AS, manufactured by Aurolab, in India. It has an equiconvex optic design, with a spheric anterior surface and an aspheric posterior one ($-0.15\ \mu\text{m}$). It comes with anterior rounded and posterior square optic edges. The hydrophilic polymer used is manufactured by Benz R&D (Sarasota, FL). This IOL has been used in hundreds of thousands of cases, without degradation of its optical quality in the long term. It comes with a piston-like injector and a foldable-type cartridge, which makes it extremely easy and flawless to implant. I am a firm advocate of loading the IOL myself and under the microscope so I can control how it folds and advances along the narrowing cartridges tunnel and ensure that everything is all right. The tip of the cartridge does not need to go all the way through the corneal incision, to achieve a safe insertion.

I went from intermittent to primary use of this implant for several reasons. I was getting excellent and consistent visual results, confirmed through patient satisfaction surveys, my own perspective, as well as that of my techs. Other reasons include ease of loading and insertion, ability to handle monovision patients wonderfully, and lack of postoperative complications. I haven't had a significant increase in posterior capsule opacification (compared to using hydrophobic acrylics), which would have led me to search other options.

My second alternative is a 3-piece aspheric, silicone implant, the Tecnis Z9002, manufactured by Abbott Medical Optics. It is the newest and improved version

of Allergan's PhacoFlex SI30/40 and the Clariflex models, which I used for many years with excellent results.

If I need to implant a toric IOL, I am more confident on the "stickiness" ability (less tendency to rotate) of the hydrophobic acrylic implants (Alcon's SN6AT or Tecnis toric lens). If I have a case where spherical and or cylinder powers are out of range, I will use a single-piece hydrophilic acrylic implant, which can be ordered in a wider range of powers (sphere $-10\ \text{D}$ to $+35\ \text{D}$, and cylinder $+1$ to $+11\ \text{D}$), manufactured by Rayner, in East Sussex, UK.

>>>Dr. Hoffman: Although many surgeons have their own "workhorse" lens that they use in the majority of their routine cases, I like to consider all of the lenses available and customize each for the patient. I use single-piece and 3-piece IOLs, hydrophilic and hydrophobic acrylic in addition to silicone and Collamer lenses, clear and blue-blocking IOLs, and monofocal, multifocal, toric, and accommodative IOLs. Each patient has anatomical and pathological variations that may make their eyes better suited for a particular lens design or lens material. In addition, they may have particular postoperative expectations or financial restrictions that may or may not allow them to be candidates for lenses that would not be covered by their insurance. Although keeping with one "routine" IOL simplifies the lens choice, I have found it more stimulating to try to customize the IOL for each individual.

2. Which IOL do you prefer for patients who have undergone myopic or hyperopic LASIK or PRK?

>>>Dr. Glikin: Laser treatment induces spherical aberration changes of the cornea. One study reported an increase of $+0.04\ \mu\text{m}$ in corneal spherical aberration for

each diopter of myopic treatment and an induction of $-0.19\ \mu\text{m}$ for each diopter of hyperopic treatment (Bottos et al, 2011).

In a post hyperopia treated patient, I will avoid adding negative spherical aberration. My preference is a spheric lens (Aurolab's FH5061 or FH5600SQ, or Alcon's SN60AT). In a post myopia treated patient, I will use an aspheric IOL, according to the patient's need. Asphericity is available in a range between 0 and $-0.27\ \mu\text{m}$, depending on the IOL manufacturer (Tecnis $-0.27\ \mu\text{m}$, Alcon IQ $-0.20\ \mu\text{m}$, Auroflex, either $0\ \mu\text{m}$ or $-0.15\ \mu\text{m}$).

Since these patients underwent refractive surgery to diminish their dependence on any type of visual aid, and most of them weren't presbyopic at that time, when it comes for lens surgery, they want to maintain their spectacle independence. IOL calculation is always a challenge in post keratorefractive patients, as the instruments used to measure corneal curvature employ a standardized index of refraction, which is no longer suitable on treated corneas.

We are much better now in targeting emmetropia than we were 5 years ago, thanks to the effort of several of our colleagues (Hill, Barrett, Olsen, Wang, Koch, Masket, to mention a few) and to the availability of new measuring instruments. But "we aren't there yet." That is why I am not a firm advocate of multifocal IOLs or toric implants in these cases. I dedicate extra chair time with patients, talking about risks and benefits. I explain monovision to them, so that if post op refraction in the dominant eye is close to emmetropia, I might aim for low myopia in the second eye, if they agree to it.

>>>Dr. Hoffman: IOL selection in patients who have undergone previous corneal refractive surgery can be customized based on the resultant corneal spherical aberration. In general, eyes that have had previous myopic LASIK or PRK will tend to have positive spherical aberration, more positive than a virgin cornea. Selecting an IOL with a large amount of negative spherical aberration can help counteract some of the positive spherical aberration induced by the myopic ablation. The opposite is true for eyes that have undergone hyperopic LASIK. These eyes have negative corneal spherical aberration and would be best served by older style IOLs that have positive spherical aberration.

The following are examples of various IOLs and their spherical aberrations: AcrySof SN60AT (Alcon Laboratories, spherical aberration [SA] = $0.28\ \mu\text{m}$), Sensar AR40e (Abbott Medical Optics, SA = $0.1\ \mu\text{m}$), Akreos TL MI60 (Bausch + Lomb, SA = $0\ \mu\text{m}$), AcrySof IQ SN60WF (Alcon, SA = $-0.2\ \mu\text{m}$), and Tecnis Z9000 (Abbott Medical Optics, SA = $-0.27\ \mu\text{m}$).

The ultimate goal is to attempt to counteract the corneal spherical aberration with an IOL with close to equal and opposite spherical aberration in order to have a total optical system with zero or slightly negative

spherical aberration. Whether patients will be able to perceive this final result ultimately depends on the relative sensitivity of each patient.

3. Do you prefer a single-piece IOL or a 3-piece IOL? Are there certain clinical situations where you use one design over the other? What lens is best tolerated in the sulcus?

>>>Dr. Glikin: Several companies manufacture their implants in single-piece or 3-piece models, sharing similar optic features. Foldable single-piece lenses are friendlier, with injectors and cartridges, and easier to insert. They allow the use of a smaller incision size, without stretching it during delivery (the tip of the cartridge doesn't enter the anterior chamber, nor the total length of the incision tunnel), and the use of a piston-like injector, which will free the nondominant hand, which can then be used to hold a spatula through the paracentesis, aiding the delivery of the lens into the bag and out of the cartridge.

If I am performing surgery at a distant location, where there are no backup lenses, and I have to order only one in advance, I choose an implant that can be placed either in the sulcus or in the bag (Tecnis Z9002 or Tecnis ZA9003, both with a rounded anterior optic edge).

If the patient has a zonular defect, either traumatic or secondary to a progressive disease (such as pseudoexfoliation syndrome), I will choose a 3-piece hydrophobic acrylic, with a rounded anterior optic edge, to be implanted either in the bag or at the sulcus, or sutured to the iris or the sclera, such as the hydrophobic acrylic Tecnis ZA9003, by Abbott Medical Optics.

If the defect appears to be large enough, I might also order an Iris Claw Aphakia lens, the Artisan AC205, manufactured by Ophtec in the Netherlands. In case the mentioned options, or sutured rings and segments are not feasible.

In situations where there is a short tear in the posterior capsule, (which I can convert into a posterior CCC) or a rent in the anterior rexis, I will avoid using 3-piece lenses in the bag, which could stretch it and extend the tear further still, during insertion. I would then use a single-piece foldable IOL, such as the ones already mentioned.

>>>Dr. Hoffman: Single-piece versus 3-piece IOLs is really just a matter of preference for routine cases with IOL placement in the bag. The advantage of single-piece IOLs is that, in general, they can be inserted through a slightly smaller incision, and this will result in less surgically induced astigmatism. The reality is that the difference in surgically induced astigmatism is quite small and almost negligible when comparing a 2.2-mm to a

2.5-mm incision. That being said, I still prefer to place a 3-piece multifocal IOL over a single-piece multifocal IOL in part to an unsubstantiated but perceived impression that 3-piece lenses center better and are less likely to decenter as easily as single-piece multifocal IOLs. This statement has no scientific evidence and is just a personal bias. Another advantage of the 3-piece design for multifocal IOLs is the option of placing the IOL in the sulcus with optic capture through the capsulorhexis, in the rare instance of a posterior capsule tear. I use both 3-piece IOLs and single-piece IOLs for my routine cases with a slight preference for the single-piece design due to their ease of insertion. The only instance where single-piece IOLs should definitely not be used is passive placement in the ciliary sulcus. These IOLs are not stable in the sulcus and have been found to cause posterior iris chafing, inflammation, and recurrent hyphemas. The best IOL for the sulcus is a 3-piece design with a large haptic-to-haptic diameter, and a rounded front surface edge to prevent pigment dispersion.

4. How often do you believe glistenings become visually significant, and how often does IOL exchange become necessary? How do you evaluate a patient with possible decreased optic clarity?

>>>Dr. Glikin: Glistenings have not been a source of complaint in my practice or in the ones of 3 other high-volume local surgeons, whom I purposely asked. We do see them at the slit lamp, but patients do not refer any significant or long term visual disturbance or complaint. Neither I nor my cited colleagues have had to explant an IOL because of this phenomenon.

We have had an epidemic of “clouded optics” in hundreds of patients in whom a single-piece hydrophilic acrylic implant was used, all manufactured by the same company. They had to be explanted and replaced. In these cases, slit-lamp examination with pupil dilation, using different illumination techniques, was enough to assess the defect, although many of these patients, who came for a second opinion, had their posterior capsules “yagged” (because of lack in understanding the issue).

In selected cases, to evaluate optic clarity of the eye, I use the HD Analyzer (former OQUAS), manufactured by Visiometrics (Barcelona, Spain).

>>>Dr. Hoffman: Glistenings are an unfortunate finding in certain IOL designs but, fortunately, their effect on visual function is very limited. Studies have demonstrated that most glistenings did not affect contrast sensitivity, glare, or visual acuity. I believe that it is extremely rare that glistenings develop to the point where IOL exchange is required; however, there are anecdotal reports of rare patients who were affected significantly enough that IOL exchange was required. Another aspect

of glistenings that is of concern is the observation that some IOLs will develop increasing glistenings with time. With this in mind, I think we should not be alarmed to see glistenings in IOLs but we should also try to avoid IOLs that are known to develop glistenings especially in younger patients who may be using those lenses for many decades. Because of the rare patient who develops increasing glistenings with time, I try to avoid these lenses in patients undergoing cataract surgery who are under 60 years of age.

The best way to assess the possible effect of glistenings on a patient's visual function is to look at his or her fundus through the affected lens using a standard 90 D lens. If the image of the fundus is clear, then the glistenings are probably having minimal effect. When the optic is calcified or the glistenings are severe and visually significant, the image of the fundus will be poor.

Personally, when it is time for me to have cataract surgery, I would prefer to have an IOL that does not have glistenings.

5. What are your thoughts on blue light-filtering IOLs?

>>>Dr. Glikin: This is a controversial matter. The literature is not conclusive. Are such IOLs beneficial? Are they detrimental? After reviewing published literature, I will answer “no” to both questions. My first choice is not usually a blue-blocking lens. But if I did implant one in one eye, I will definitely use the same model in the fellow eye.

>>>Dr. Hoffman: I believe that the potential advantages and drawbacks of blue-blocking IOLs have been greatly exaggerated by individuals on both sides of the debate. Proponents of blue-blocking IOLs claim that they protect the retina from the harmful blue/UV spectrum and are protective in patients with macular drusen and age-related macular degeneration (AMD). Opponents claim that the loss of the near UV/blue spectrum causes difficulties with circadian rhythms, depression, and distortion of color perception. I have used blue-blocking IOLs and still use them on occasion; however, my reasons for utilizing these lenses fall outside of the current debate focus.

I have found that on rare occasions, some of my postoperative cataract patients complained bitterly of light sensitivity to the point that they were “unable to stand next to an open window.” These complaints often persisted for 6–12 months or more after the surgery, and they could not be attributed to postoperative inflammation. I started using blue-blocking IOLs to determine if I could eliminate these rare complaints and anecdotally, the blue-blocking IOLs did appear to reduce or eliminate these symptoms. If I have a patient preoperatively

who appears to have unusual light sensitivity that was present prior to the development of cataract, I will use these lenses. I will also sometimes use them in patients with macular drusen or AMD just in case the proponents of the use of blue-blockers for retinal protection are correct. I have never had a patient complain of difficulty with insomnia, depression, or color perception after being implanted with a blue-blocking IOL.

Although these lenses are not supposed to affect color perception, there have been rare instances of patients implanted with a blue-blocker in one eye and a clear lens in the other eye, who did notice a difference in color perception. So, if you are going to implant these lenses, I would advise using them bilaterally and not mixing blue-blockers with clear lenses. And if a patient presents with a blue-blocker in one eye or a clear lens in one eye, and requires cataract surgery in the second eye, the second eye should have an IOL with the same optical qualities to avoid the rare instance of color perception imbalance.

6. How do you counsel patients with coexisting age-related macular degeneration (AMD) regarding choice of IOL design and aim for cataract surgery?

>>>>Dr. Glikin: Management of a patient with coexisting cataract and AMD presents a challenge for the cataract surgeon, the retina specialist, and the patient. Usually both cataract and macular pathology appear to be contributing to decreased visual acuity. "Will cataract surgery improve my vision?" and "Will cataract surgery worsen my AMD?" are common questions. In 2012, Casparis et al (see "Suggested Reading") reported that "At this time, it is not possible to draw reliable conclusions from the available data, to determine whether cataract surgery is beneficial or harmful in people with AMD." I share this with my patients, as well as the information on blue-blocking IOLs. I encourage them toward web search. If ultimately they find these lenses beneficial, then I will use a "yellow tinted" single-piece hydrophobic acrylic, such as Alcon's SN60AT or SN60WF. Otherwise I use the lenses listed under the first question.

If they have a significant cataract, I explain the importance of at least gaining visual field ability by removing it, even if they won't get reading vision.

I have had no experience yet with the Implantable Miniature Telescope IOLs, such as the LMI or the Ori Lens, manufactured by OptoLight in Israel, nor with the +8 add IOLs such as the Lentis LS-313 MF80, manufactured by Oculentis in Germany. Data up to date show promising results. This might be a way of helping these cases with advanced maculopathy.

All of my patients, prior to surgery, whether symptomatic or not, have a macular spectral-domain OCT done (and eventually a digital fluorescein angiogram).

Depending on the case, I will inject an anti-VEGF agent prior to or simultaneously with lens surgery.

I will closely monitor postoperative inflammation and macular behavior, and I advise the patient on using a grid or at least checking his or her vision on vertical and horizontal lines or shapes.

>>>>Dr. Hoffman: When presented with the AMD patient who would benefit from cataract surgery, I inform the patient of the limitations of cataract surgery in the presence of his or her pathology. I also discuss the studies that demonstrate a possible but inconclusive protective effect from blue-blocking IOLs and allow them to make an informed decision. Most will opt for the blue-blocking IOLs. I then have a discussion regarding postoperative refractive aim. Some patients who are nearsighted preoperatively prefer to be left nearsighted, others like the idea of seeing at distance without glasses. Again, I leave this decision up to the patient. Many times this depends on what the majority of their day is spent doing. An avid reader prefers seeing up close without glasses. An avid television watcher prefers distance. I do not recommend monovision or multifocal IOLs due to the possibility of monocular visual loss and the limited visual acuity that can develop with a multifocal lens in the presence of macular pathology. I make patients aware of the existence of accommodating IOLs but I usually do not hard sell them because of the limited near acuity; however, if the patient is appropriately informed and understands the limitations and wishes to have a presbyopia IOL, an accommodating IOL is an option for these patients.

7. What is your preferred presbyopia implant solution and why?

>>>>Dr. Glikin: My preferred presbyopia treatment is monovision, after ruling out ocular misalignment, screening for eye dominance and patient understanding on how his or her eyes will function. I use the Auroflex FH5600AS, the Tecnis Z9002, or the Tecnis Z9003. I aim for between -0.75 D and -2.0 D, depending on the patient's habits, needs, and previous refractive error.

If the patient has a preference for multifocality, understands the risks and possible side effects and I find no contraindication for their use, I will implant a single-piece hydrophobic acrylic (+2.50 D or +3.0 D add, depending on the case), such as Alcon's IQ Restore, or one of the newer multifocal/bifocal hydrophilic acrylics, such as the Lentis MPlus X (+3.0 add) or the Lentis Comfort (+1.50 add), manufactured by Oculentis BV in the Netherlands.

>>>>Dr. Hoffman: If a patient who is about to undergo cataract surgery has been utilizing monovision with contact lenses, the easiest and least expensive approach for

these patients is to give them monovision with monofocal IOLs. They have already demonstrated tolerance for monovision and will be happy with their postoperative result as long as the IOL calculations are on target.

For most other patients requesting presbyopia correction, I prefer a diffractive multifocal IOL. The refractive IOLs have a higher instance of halos and glare and I have found that, if placed in an appropriate candidate, the diffractive multifocal IOLs are more likely to give excellent near acuity, with a low instance of long-term intolerable glare or halos. In patients who are adverse to the possibility of nighttime glare or patients who have macular or corneal pathology (including post radial keratotomy eyes), I will offer accommodating IOLs with a comprehensive discussion of the limitations of near vision with these lenses. If a patient is not able to understand the nuances of glare or the possible need for computer or reading glasses following placement of any of these lenses, then I encourage him or her to consider a monofocal IOL.

8. What is your experience with dysphotopsias? Do certain IOLs create these phenomena more than others do? How can these be addressed if they do not resolve?

>>>Dr. Glikin: Dysphotopsia can occur with any type of IOL material and design, as well as in anatomically “perfect” postoperative lens surgery. In my practice as well as in those of 3 high-volume colleagues with whom I consulted, photic phenomenon have been transient, and patients expressed mild to moderate complaints, never requiring surgical intervention.

Reviewing the literature, I find that there seems to be no proven clear etiology to date. Treatment options have been mostly based upon a trial-and-error basis. What works OK in some cases, doesn't in others. The options in cases of negative dysphotopsia, of either prolapsing the capsulorrhexis under the optic edge (reverse optic capture) or “obscuring” the capsulorrhexis–optic edge junction with a secondary sulcus-placed IOL, thus avoiding the risks of lens exchange, seem wise. Nevertheless, this has been described as working in some patients, but not in all.

If I had a case that required surgical intervention, I would begin by prolapsing the IOL's optic above the capsulorrhexis. If this technique wasn't feasible, or failed, then a piggyback lens would be my preference. First choice is Rayner's Sulcoflex, a single-piece hydrophilic acrylic designed exclusively for sulcus placement, either plano or powered. It comes with an optic diameter of 6.5 mm, rounded optic and haptic edges, and an overall length of 14 mm. Another option is the Tecnis Z9002. Staar's AQ 2010V is not currently available where I practice.

Some patients may be particularly sensitive to dysphotopsia, and may require additional surgical treatment. In others, it might be that reassurance on what they perceive is a common and expected phenomenon that will improve over time, will ease their “negative” feelings about the results of their surgery (not meeting preoperative expectations).

>>>Dr. Hoffman: I have been fortunate in my career. Most of the patients I have seen with dysphotopsias have improved spontaneously with time and to date I have not had to remove any IOLs. The one patient I did see (from another surgeon) who insisted on an IOL exchange, frightened me so badly that I referred her out to a “specialist in another state.”

Acrylic IOLs with a high refractive index and square edges on the front and back surfaces are the most likely IOLs to cause negative crescentic scotomas, but I have seen complaints with all lens designs and lens materials. Luckily, most of these complaints will improve with time and the best initial treatment is handholding and reassurance. If the symptoms do not abate after 6–12 months, then intervention is needed. Pilocarpine and brimonidine are not very effective for these patients, and they will usually require some form of surgical intervention.

IOL exchange with a silicone or Collamer IOL with rounded edges has been found to be very effective in these patients and has the potential of turning a very angry unhappy individual into a very grateful one. Another effective option is placement of a piggyback IOL in the ciliary sulcus on top of the offending acrylic IOL. The material of the piggyback lens does not seem to make a difference in its effectiveness. If the patient has a slight refractive error, attempting to adjust the final refractive result with a low-powered piggyback IOL can also add to the happy factor. The piggyback IOL is a great option for the patient who presents with symptoms of long duration wherein an IOL exchange would be complicated, or the patient who had undergone an unsuccessful YAG capsulotomy in the hopes that this would alleviate the symptoms. A final option is to attempt to change the relationship of the anterior capsulorrhexis to the IOL optic by either prolapsing the optic in front of the capsulorrhexis or widening the capsulorrhexis beyond the edge of the IOL.

Ricardo G. Glikin, MD, is currently in private practice in Buenos Aires, Argentina. At the time of preparing his remarks, he was Chief of the Cataract Section at the Hospital de Clínicas José de San Martín, University of Buenos Aires, Argentina.

Richard S. Hoffman, MD, is a practicing ophthalmologist with Drs. Fine, Hoffman and Sims, LLC, in Eugene, Oregon. He is also a clinical associate professor of ophthalmology at the Casey Eye Institute, Oregon Health & Science University.

SUGGESTED READING

Bottos KM, Leite MT, Aventura-Isidro M. Corneal asphericity and spherical aberration after refractive surgery. *J Cataract Refractive Surg.* 2011;37(6):1109–15.

Casparis H, Lindsley K, Kuo IC, Sikder S, Bressler NB. Surgery for cataracts in people with age-related macular degeneration. *Cochrane Database Syst Rev.* 2012 Jun 13;6:CD006757.

Chew EY, Sperduto RD, Milton RC, et al. Risk of advanced age-related macular degeneration after cataract surgery in the Age-Related Eye Disease Study: AREDS report 25. *Ophthalmology.* 2009;116(2):297–303.

David E, Hardten DR, Lindstrom R. *Presbyopic Lens Surgery: A Clinical Guide to Current Technology.* Thorofare, NJ: Slack; 2007.

Dewey S. Posterior capsule opacification. *Curr Opin Ophthalmol.* 2006; 17(1):45–53.

Fine IH. The evolution of phacoemulsification. *CRST.* September 2007.

Holladay JT. *Quality of Vision: Essential Optics for the Cataract and Refractive Surgeon.* Thorofare, NJ: Slack; 2006.

Hovanesian JA. *Premium Cataract Surgery: A Step-by-Step Guide.* Thorofare, NJ: Slack; 2012.

Pallikaris IG, Kontadakis GA, Portaliou DM. Real and pseudoaccommodation in accommodative lenses. *J Ophthalmol.* 2011;2011:284961.

Lai E., Levine B, Ciralsky J. Ultraviolet-blocking intraocular lenses: fact or fiction. *Curr Opin Ophthalmol.* 2014 Jan;25(1):35–9.

Mamalis N. Negative dysphotopsia following cataract surgery. *J Cataract Refract Surg.* 2010;36(3):371–2.

Masket S, Fram NR. Pseudophakic negative dysphotopsia: surgical management and new theory of etiology. *J Cataract Refract Surg.* 2011; 37(7):1199–207.

Norrby S. Sources of error in intraocular lens power calculation. *J Cataract Refract Surg.* 2008;34(3):368–76.

Packer M, Fine IH, Hoffman RS. Aspheric intraocular lens selection: the evolution of refractive cataract surgery. *Curr Opin Ophthalmol.* 2008; 19(1):1–4.

Packer M, Fine IH, Hoffman RS, Piers PA. Improved functional vision with a modified prolate intraocular lens. *J Cataract Refract Surg.* 2004;30(5):986–92.

Pallikaris IG, Kontadakis GA, Portaliou DM. Real and pseudoaccommodation in accommodative lenses. *J Ophthalmol.* 2011;2011: 284961.

Steinert RF. *Cataract Surgery: Techniques, Complications and Management.* 3rd ed. Philadelphia: Saunders; 2010.

Vock L, Menapace R, Stifter E, Georgopoulos M, Sacu S, Bühl W. Posterior capsule opacification and neodymium:YAG laser capsulotomy

rates with a round-edged silicone and a sharp-edged hydrophobic acrylic intraocular lens 10 years after surgery. *J Cataract Refract Surg.* 2009;35(3):459–65.

Waite A, Faulkner N, Olson RJ. Glistenings in the single-piece, hydrophobic, acrylic intraocular lenses. *Am J Ophthalmol.* 2007;144(1): 143–4.

Werner L. Glistenings and surface light scattering in intraocular lenses. *J Cataract Refract Surg.* 2010;36(8):1298–420.

Zhu XF, Zou HD, Yu YF, Sun Q, Zhao NQ. Comparison of blue light-filtering IOLs and UV light-filtering IOLs for cataract surgery: a meta-analysis. *PLoS One.* 2012;7(3):e33013.

Of Historical Interest

Apple DJ. *Sir Harold Ridley and His Fight for Sight: He Changed the World So That We May Better See It.* Thorofare, NJ: Slack; 2006.

Apple DJ. *Foldable Intraocular Lenses: Evolution, Clinicopathologic Correlations, and Complications.* Thorofare, NJ: Slack; 2000.

Apple DJ, Werner L. Complications of cataract and refractive surgery: a clinicopathological documentation. *Trans Am Ophthalmol Soc.* 2001; 99:95–109.

Azar DT. *Intraocular Lenses in Cataract and Refractive Surgery.* Philadelphia: Saunders; 2001.

Gimbel HV, Neuhann T. Development, advantages, and methods of the continuous circular capsulorhexis technique. *J Cataract Refract Surg.* 1990;16(1):31–7.

Guirao A, Redondo M, Artal P. Optical aberrations of the human cornea as a function of age. *J Opt Soc Am A.* 2000;17(10):1697–702.

Mainster MA. Solar retinitis, photic maculopathy and the pseudophakic eye. *J Am Intraocular Implant Soc.* 1978;4(3):84–6.

Nishi O, Nishi K, Akura J. Speed of capsular bend formation at the optic edge of acrylic, silicone, and poly(methyl methacrylate) lenses. *J Cataract Refract Surg.* 2002;28(3):431–7.

Oshika T, Shiokawa Y, Amano S, Mitomo K. Influence of glistenings on the optical quality of acrylic foldable intraocular lens. *Br J Ophthalmol.* 2001;85(9):1034–7.

Ridley H. Intra-ocular acrylic lenses: A recent development in the surgery of cataract. *Br J Ophthalmol.* 1952;36(3):113–22.

Related Academy Materials

Lens and Cataract. Basic and Clinical Science Course, Section 3, 2015–2016.

Clinical Optics. Basic and Clinical Science Course, Section 3, 2015–2016.

